Downloaded from www.ajronline.org by Unikilinik RWTH Aachen on 03/06/26 from IP address 134.130.15.1. Copyright ARRS. For personal use only; all rights reserved

AJR FOCUS ON:

The Value of a Multidisciplinary Approach to the Diagnosis of Usual Interstitial Pneumonitis and Idiopathic Pulmonary Fibrosis: Radiology, Pathology, and Clinical Correlation

Jonathan H. Chung[1]
David A. Lynch[2]

OBJECTIVE. Multidisciplinary discussion is essential in establishing the diagnosis of idiopathic pulmonary fibrosis (IPF) and in determining prognosis.

CONCLUSION. The CT and histopathologic correlate for IPF is usual interstitial pneumonitis (UIP). If a high-confidence diagnosis of UIP is made on CT, IPF is almost always the diagnosis, obviating lung biopsy. If a confident diagnosis of UIP cannot be made on CT, further assessment with lung biopsy and multidisciplinary discussion are often necessary to achieve a confident final diagnosis.

Keywords: atypical usual interstitial pneumonitis, CT, idiopathic pulmonary fibrosis (IPF), multidisciplinary discussion, usual interstitial pneumonitis (UIP)

DOI:10.2214/AJR.15.15627

Received September 9, 2015; accepted without revision September 25, 2015.

[1]Department of Radiology, The University of Chicago Medicine, 5841 S Maryland Ave, P210B, Chicago, IL 60637. Address correspondence to J. H. Chung (jonherochung@uchicago.edu).

[2]Department of Radiology, National Jewish Health, Denver, CO.

This article is available for credit.

AJR 2016; 206:463–471

0361–803X/16/2063–463

© American Roentgen Ray Society

Idiopathic pulmonary fibrosis (IPF) is the most common and most fatal type of pulmonary fibrosis. The diagnosis of IPF requires exclusion of other known causes of pulmonary fibrosis; in most cases of pulmonary fibrosis, no underlying cause is found. Patients with IPF tend to be elderly, and men are affected more often than women. A diagnosis of IPF carries a poor prognosis, although the prognosis can be augmented by concomitant clinical factors. Until recently, there was no effective medical therapy for IPF. Treatment mainly focused on the mitigation of comorbidities known to exacerbate the disease or associated with a poor prognosis. Recently, two new medications were approved by the U.S. Food and Drug Administration for the treatment of IPF after they were shown to slow the decline in pulmonary function over time, which has renewed interest in the accurate diagnosis of IPF [1–3].

The diagnosis of IPF and of other types of pulmonary fibrosis requires multidisciplinary review for optimal accuracy. The inclusion of the pulmonary, radiology, and pathology teams ensures that patients will receive the most accurate diagnosis possible; however, even with a multidisciplinary approach, determining the correct diagnosis can be challenging. Discrepancies in diagnoses between different specialists and low confidence in diagnosis are common occurrences and are best resolved cooperatively. In addition to diagnostic considerations, multidisciplinary discussion may also be helpful in determining patient prognosis. This article will present a broad overview of the clinical, imaging, and pathologic findings in IPF and then discuss the value of a multidisciplinary approach in the diagnosis of IPF from the vantage point of a chest radiologist.

Clinical Features of Idiopathic Pulmonary Fibrosis

Patients with IPF most often present with progressive dyspnea on exertion and a chronic dry cough. Digital clubbing, chest pain, fatigue, malaise, and weight loss are other nonspecific symptoms. Pulmonary function test results may be normal in patients with mild disease but will show some degree of restriction (i.e., reduced vital capacity and reduced total lung capacity but preserved residual volume). Diffusion capacity is commonly decreased even in patients with mild disease, although this finding is nonspecific. Increasingly, patients present with early interstitial lung disease discovered incidentally on CT performed for other reasons [4, 5].

Patients with IPF are usually older than 50 years old; a diagnosis of IPF in someone younger than 40 years old would be highly unusual [6, 7]. Additionally, pulmonary fibrosis in a patient older than 70 years old is almost always IPF [8]. Cigarette smoking is also moderately associated with IPF: 60% of patients with IPF are current or former smokers [9]. Genetic factors clearly play a role in IPF; 5–20% of patients with IPF have a family history of interstitial lung disease or pulmonary fibrosis [10]. Gastroesophageal

Downloaded from www.ajronline.org by Unikilinik RWTH Aachen on 03/06/26 from IP address 134.130.15.1. Copyright ARRS. For personal use only; all rights reserved

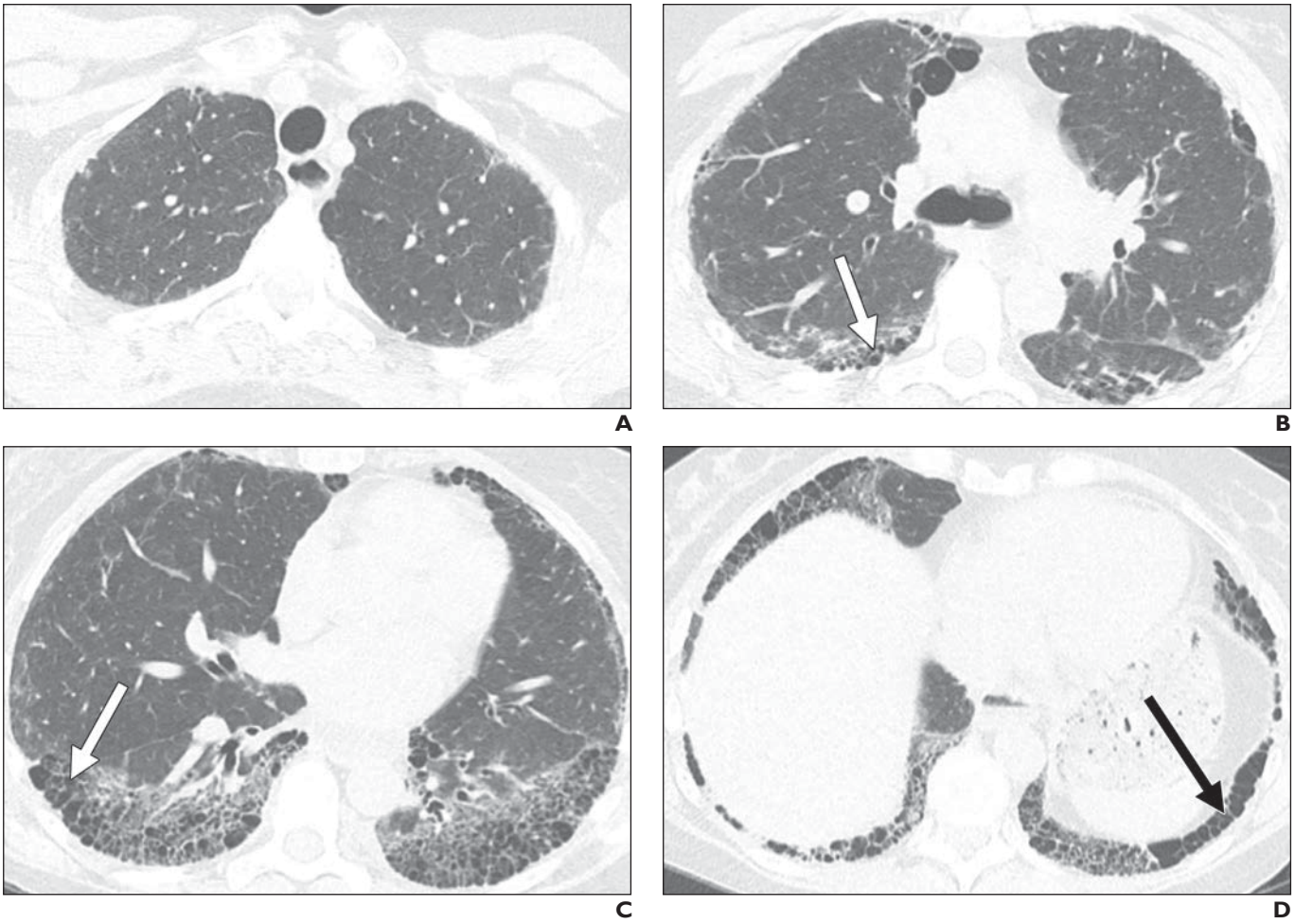

Fig. 1—71-year-old man with shortness of breath and crackles on auscultation.
A–D, Axial high-resolution CT images show peripheral and basilar-predominant pulmonary fibrosis and clustered honeycombing (*arrows,* **B–D**) in subpleural lung in this patient with usual interstitial pneumonitis pattern of pulmonary fibrosis.

reflux also appears to be associated with pulmonary fibrosis and is associated with worse survival [11, 12].

CT Diagnosis of Idiopathic Pulmonary Fibrosis

Usual interstitial pneumonitis (UIP) is the imaging and histologic correlate for IPF. UIP on high-resolution CT (HRCT) usually presents with findings of pulmonary fibrosis including reticulation, traction bronchiectasis, traction bronchiolectasis, and honeycombing (Fig. 1). Honeycombing is diagnostic of end-stage fibrosis and typically presents on CT as "clustered cystic airspaces, typically of comparable diameters on the order of 3–10 mm" [13]; honeycombing arises in the most peripheral aspects of the lungs [13] (Fig. 1). Honeycombing is highly suggestive of UIP on imaging and is present in most patients with UIP [14–17]. UIP is most often peripheral and most often involves the lung bases, although some degree of upper lobe involvement is typical. Occasionally, UIP may be upper lobe–predominant, although this finding should always suggest the possibility of alternative diagnoses [18]. However, a nonperipheral distribution of fibrosis is highly atypical because more than 90% of UIP

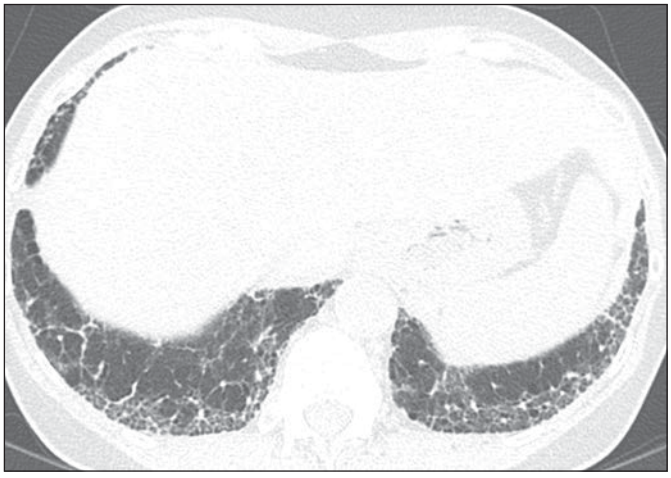

Fig. 2—63-year-old man with idiopathic pulmonary fibrosis. Axial CT image shows mild ground-glass opacity superimposed on reticulation and traction bronchiolectasis in posterior costophrenic angles (possible usual interstitial pneumonitis pattern) most consistent with microscopic fibrosis.

Downloaded from www.ajronline.org by Unikilinik RWTH Aachen on 03/06/26 from IP address 134.130.15.1. Copyright ARRS. For personal use only; all rights reserved

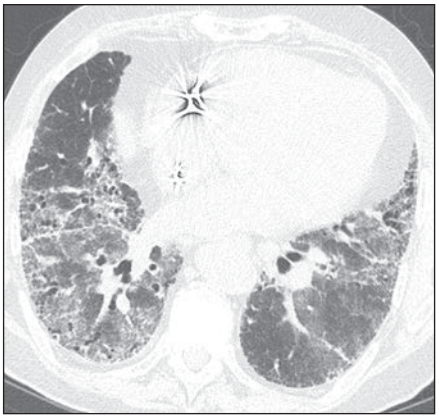

Fig. 3—79-year-old man with acute shortness of breath in setting of idiopathic pulmonary fibrosis. Patchy ground-glass opacity in lower lung zones, which represents acute exacerbation of pulmonary fibrosis, is present on axial chest CT image.

Fig. 4—81-year-old man with known pulmonary fibrosis. Coronal CT image shows basilar and peripheral pulmonary fibrosis with honeycombing in usual interstitial pneumonitis pattern. Focal nodule (*arrow*) is present in right lower lobe and was shown to be adenocarcinoma.

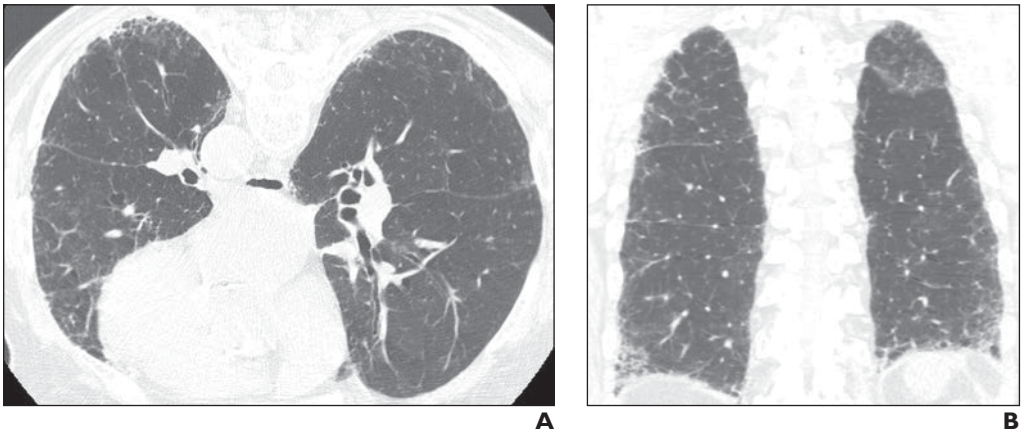

Fig. 5—72-year-old man with crackles on examination.
A and **B,** Axial (**A**) and coronal (**B**) CT images show basilar and peripheral pulmonary fibrosis without honeycombing; these findings indicate possible usual interstitial pneumonitis pattern.

cases are peripheral-predominant. A substantial degree of ground-glass opacity is unusual in UIP except in patients with superimposed infection, acute exacerbation, or pulmonary edema [19]. In patients with UIP, mild ground-glass opacity typically represents pulmonary fibrosis beyond the resolution of chest CT, especially if it occurs in areas of obvious fibrosis (Fig. 2). If ground-glass opacity occurs in an area of nonfibrotic lung, then acute exacerbation, superimposed infection, or aspiration should also be considered [20, 21] (Fig. 3). If an area of focal consolidation or a nodular lesion is incidentally noted in areas of pulmonary fibrosis, then close follow-up is mandated because pulmonary fibrosis is a significant risk factor for the development of lung cancer, usually squamous cell carcinoma or adenocarcinoma [22] (Fig. 4).

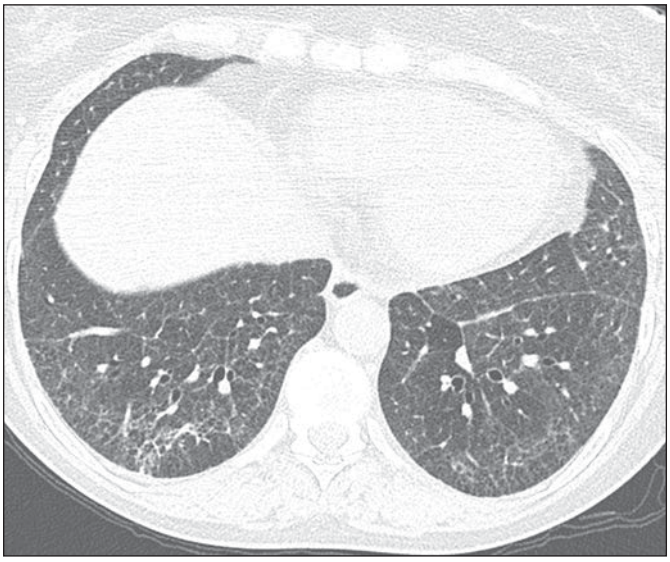

Fig. 6—48-year-old woman with scleroderma. Axial CT image shows mild fibrosis (reticulation and mild traction bronchiectasis, as well as bronchiolectasis) most concentrated in peribronchovascular region with relative subpleural sparing (inconsistent with usual interstitial pneumonitis [UIP], highly suggestive of nonspecific interstitial pneumonitis); his pattern would be unusual for UIP.

The current guidelines support three categories of UIP diagnosis on chest CT: definite UIP, possible UIP, and inconsistent with UIP [23]. To establish a definite UIP diagnosis based on chest CT, there must be reticular pulmonary fibrosis that is basilar and subpleural-predominant, honeycombing with or without traction bronchiectasis, and no other features that suggest another diagnosis (Fig. 1). In addition to patients with IPF, a definite UIP CT pattern may be found in patients with collagen vascular disease, occupational lung disease, familial pulmonary fibrosis, hypersensitivity pneumonitis (HP), or drug-related pulmonary fibrosis.

Possible UIP on CT has all the features of definite UIP except that there is no honeycombing (Fig. 5). However, the identification of honeycombing on noncontiguous images or in cases of mild disease is often challenging. Even expert readers may struggle with this

Downloaded from www.ajronline.org by Unikilinik RWTH Aachen on 03/06/26 from IP address 134.130.15.1. Copyright ARRS. For personal use only; all rights reserved

issue, as implied by the modest interreader agreement in the identification of honeycombing in one study (mean κ = 0.45) [24].

The category "inconsistent with UIP" implies that an alternative diagnosis to UIP should be considered on the basis of the presence of one or more of the following CT findings: upper or mid lung predominance, peribronchovascular predominance, extensive ground-glass opacity (more extensive than reticulation), profuse micronodules, multiple discrete cysts not consistent with honeycombing, diffuse mosaic attenuation or air trapping involving three or more lobes and bilateral, and consolidation (Figs. 6 and 7). Individuals with CT patterns of possible UIP or inconsistent with UIP need further multidisciplinary workup. In these cases, lung biopsy is sometimes required to establish a confident diagnosis.

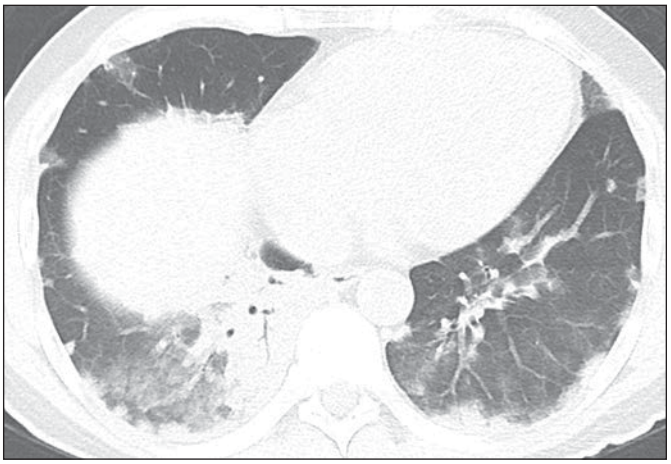

Fig. 7—64-year-old woman with subacute shortness of breath. Axial CT image shows extensive consolidation and ground-glass opacity in lungs, both of which are inconsistent with usual interstitial pneumonitis. These CT findings were shown to represent organizing pneumonia.

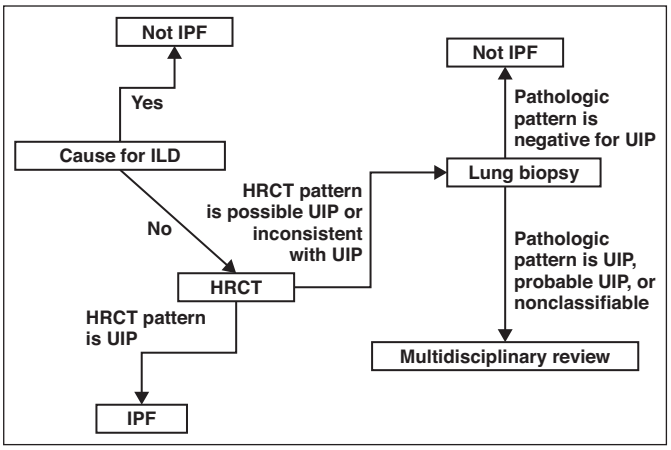

Fig. 8—Algorithm of multidisciplinary discussion in diagnosis of idiopathic pulmonary fibrosis (IPF) in patients with suspected interstitial lung disease (ILD). HRCT = high-resolution CT, UIP = usual interstitial pneumonitis.

Pathologic Features of Idiopathic Pulmonary Fibrosis

UIP is characterized on pathologic examination by patchy fibrotic regions at different stages of maturity and normal lung or mildly fibrotic lung interspersed with areas of advanced pulmonary fibrosis [25]. Fibrosis shows temporal and spatial nonuniformity. Architectural distortion with microscopic honeycombing or scarring is usually present. The paraseptal and subpleural portions of the lungs are most severely affected. Fibroblastic foci, which represent ongoing injury and repair in the lung, are the earliest manifestation of UIP on pathology [26]. Fibroblastic foci also have prognostic ramifications because they are associated with poor survival [27]. Abnormal airspaces in microscopic honeycombing are lined by hyperplastic alveolar pneumocytes (type II) and bronchiolar epithelium. Inflammation, if present, is mild and composed of lymphocytes and plasma cells. Extensive cellularity argues against the diagnosis of UIP. Discordant pathologic patterns may be found in different portions of lung—for example, UIP in one lobe with nonspecific interstitial pneumonitis (NSIP) in another lobe—and support biopsy of more than one lobe of lung for pathologic characterization [28, 29]. In these discordant cases, the prognosis is driven by the UIP histology.

The current guidelines support five diagnostic categories of UIP on histopathology: UIP, probable UIP, possible UIP, not UIP, and nonclassifiable fibrosis. A UIP pattern requires the presence of marked fibrosis or architectural distortion with or without honeycombing in a predominantly subpleural or paraseptal distribution, patchy lung involvement, and fibroblast foci without features suggestive of an alternative diagnosis. The probable UIP pattern should be considered if there is evidence of marked fibrosis or architectural distortion with or without honeycombing; either patchy involvement or fibroblastic foci, but not both, are present; if features suggestive of an alternative diagnosis are absent; or if only honeycombing is found (e.g., cases in which end-stage fibrotic lung is sampled). Possible UIP is considered if there is patchy or diffuse involvement of lung parenchyma with or without interstitial inflammation, if there are no findings of high-confidence UIP on histopathology, and if there are no findings suggestive of an alternative diagnosis. Findings that lead to a "not UIP" diagnosis on histopathology include hyaline membranes, significant organizing pneumonia, significant granulomas, severe inflammation away from honeycombing, predominantly airway-centered changes, or other features suggestive of an alternative diagnosis. As implied by the name "nonclassifiable fibrosis," this diagnosis is assigned if the pattern does not fit into the aforementioned UIP diagnostic categories.

Multidisciplinary Review in Diagnosis

The algorithm for the diagnosis of IPF is summarized in Figure 8. In patients with suspected pulmonary fibrosis, the first step is a clinical workup to assess whether there are any known causes of pulmonary fibrosis. If there are no known causes of pulmonary fibrosis, then the next step in evaluation is HRCT. Although there is no standardized HRCT protocol, the basic requirements for HRCT include thin-section reconstructions or acquisitions (1 mm), a sharp reconstruction algorithm, imaging during full inspiration, and cessation of respiratory motion during imaging. Coronal imaging is helpful to identify disease distribution and often facilitates the identification of honeycombing. Prone images are helpful to exclude subsegmental atelectasis at the lung bases, which may mimic early-stage fibrosis. Expiratory images are helpful to exclude air trapping,

TABLE 1: Current Guidelines [23] Outlining the Consensus Idiopathic Pulmonary Fibrosis (IPF) Diagnosis Based on the Combination of High-Resolution CT (HRCT) and Pathologic Diagnoses

HRCT Pattern	Pathologic Pattern				
	UIP	Probable UIP	Possible UIP	Nonclassifiable Fibrosis	Not UIP
Definite UIP	IPF	IPF	IPF	IPF	Not IPF
Possible UIP	IPF	IPF	Probable IPF[a]	Probable IPF[a]	Not IPF
Inconsistent with UIP	Possible IPF[a]	Not IPF	Not IPF	Not IPF	Not IPF

Note—UIP = usual interstitial pneumonitis.
[a]Requires multidisciplinary discussion.

which would be suggestive of HP or collagen vascular disease [30].

If the CT pattern is definite UIP, lung biopsy and multidisciplinary review are usually not necessary given the high accuracy of this CT pattern for UIP. If the CT pattern is either possible UIP or inconsistent with UIP, the next step is often lung biopsy. Transbronchial biopsy is unreliable in the diagnosis of UIP; surgical lung biopsy should be pursued when possible, and multidisciplinary review will be important. However, this type of discussion can be time-consuming and is not incentivized by current payment models. The question arises, Why is multidisciplinary review necessary? Although sometimes difficult to coordinate, this discussion among clinicians, radiologists, and pathologists has been shown to decrease interreader variation in the final diagnosis and increase diagnostic confidence [31, 32].

In one study, clinicians, radiologists, and pathologists reviewed 58 consecutive cases of suspected idiopathic interstitial pneumonia [31]. The study was performed in a stepwise fashion. In the first step, clinicians and radiologists provided their diagnostic opinion and level of confidence based only on CT images initially and then provided their diagnostic opinion and level of confidence after inclusion of clinical information. The clinicians and radiologists were then allowed to discuss the cases and change their opinions about the diagnosis. In the next step, the pathologists presented their interpretation of the surgical lung samples and the clinical and CT data were again reviewed. Then, after discussing each case, each pulmonologist, radiologist, and pathologist assigned a diagnostic opinion and a level of confidence. In the final step, if there was disagreement, all participants discussed the case to reach a final consensus diagnosis. In half of cases, the radiologists changed their diagnosis on the basis of multidisciplinary review. The pulmonologists changed their original diagnosis in approximately one-third of the cases. Importantly, the pathologic diagnosis was changed by multidisciplinary review in approximately one-fifth of the cases. Although pathology is considered the reference standard in the diagnosis of most conditions, there is no true single reference standard in the setting of interstitial lung disease. This limitation of pathology is especially true if the pathologist evaluating the specimens is not highly specialized in interstitial lung disease assessment [32]. Rather, a team approach—with the input of expert pulmonologists, radiologists, and pathologists—is necessary to achieve the best final diagnosis.

Highlighting the need for a multidisciplinary review is the substantial interobserver variation among pathologists in the assessment of interstitial lung disease and the issues with diagnostic confidence. Among pathologists in the community, there is high interreader variation ($\kappa = 0.14$) as compared with those in academic centers ($\kappa = 0.53–0.57$). Interestingly, this high variability among community pathologists is partially mitigated by multidisciplinary review ($\kappa = 0.41$) [32]. In another study of 10 academic pathologists, there was poor agreement between readers in the diagnosis of interstitial lung disease, with an overall kappa value of only 0.38 even in the first-choice diagnosis [33]. Moreover, a high-confidence diagnosis could be achieved in only 39% of cases [33]; in 18% of cases, the first-choice diagnosis could be made with only low confidence [33].

Although multidisciplinary review has been regarded as essential in the diagnosis of interstitial pneumonia, the mechanism for performing these reviews has not been standardized [3]. In its classic form, the review is performed at a conference attended by pulmonologists, radiologists, and pathologists; during the conference, the clinical details and radiologic and pathologic images are available. This conference provides an opportunity for all physicians involved to understand an individual case. For reasons of efficiency, these conferences are often reserved for cases that pose a particular diagnostic or therapeutic dilemma. In many other cases, multidisciplinary review, usually adjudicated by the pulmonologist, occurs informally at the workstation or over the telephone. With the increased recognition of the importance of overt and occult forms of collagen vascular disease as causes of interstitial lung disease [34, 35], the input of rheumatologists is increasingly necessary [23, 34, 35]. Other health professionals often involved in multidisciplinary reviews include genetic counselors and occupational health specialists.

Radiology-Pathology Correlation

The current guidelines outline consensus IPF diagnosis based on the combination of CT and pathologic diagnoses [23] using the matrix shown in Table 1. Most of the studies that have evaluated the accuracy of CT in the diagnosis of interstitial lung disease have relied heavily, if not solely, on pathology as the reference standard. As we mentioned earlier, the pathology reference standard is not robust in this setting. However, outside the multidisciplinary discussion, pathology is the most accurate tool clinicians have for diagnosing interstitial lung disease. When UIP is the first-choice diagnosis on chest CT, the diagnosis is usually concordant with pathology (≈ 80–90%) [14, 36–39]. Moreover, if a confident CT diagnosis of UIP can be achieved, the concordance with pathology increases even further (range, ≈ 90–100%) [14, 36–39] it is in this setting in which CT has the most diagnostic influence in the workup of patients with interstitial lung disease because tissue sampling is obviated and a final diagnosis of IPF can be made. However, in approximately half of patients who are ultimately diagnosed with IPF, a confident UIP diagnosis cannot be achieved on chest CT [40, 41].

With the decline in the number of lung biopsies being performed in patients with clin-

Downloaded from www.ajronline.org by Unikilinik RWTH Aachen on 03/06/26 from IP address 134.130.15.1. Copyright ARRS. For personal use only; all rights reserved

Downloaded from www.ajronline.org by Unikilinik RWTH Aachen on 03/06/26 from IP address 134.130.15.1. Copyright ARRS. For personal use only; all rights reserved

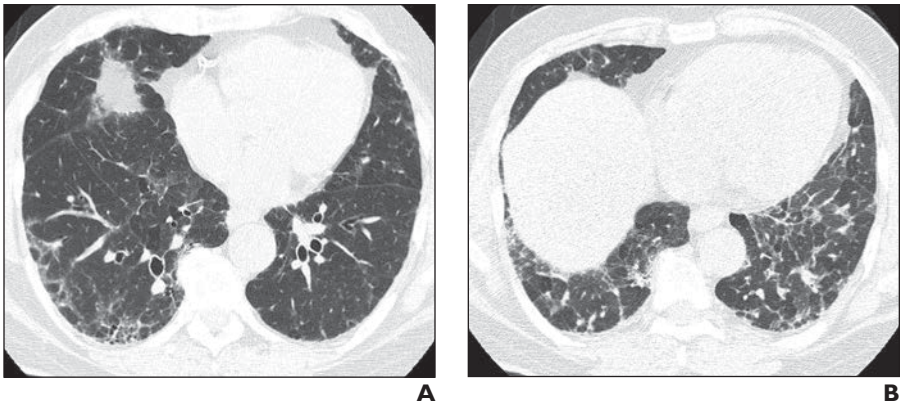

Fig. 9—56-year-old woman with atypical usual interstitial pneumonitis (UIP) on CT.
A, Axial CT image obtained during inspiration shows peripheral reticulation, ground-glass opacity, traction bronchiolectasis, and superimposed mosaic attenuation.
B, Expiratory phase CT image shows that mosaic attenuation represents severe air trapping. CT diagnosis of hypersensitivity pneumonitis was made. Pathologic pattern showed UIP, and patient was diagnosed with idiopathic pulmonary fibrosis.

ical findings and CT appearances typical of UIP, there is increasing awareness that individuals who have CT features that are "inconsistent with UIP" may have histologic UIP and a clinical diagnosis of IPF. The percentage of patients with UIP on pathology but with a CT pattern suggestive of an alternative diagnosis ranges from 26% to 62% [39, 42, 43]. The CT patterns found in these atypical cases of histologic UIP are often suggestive of NSIP, HP, or sarcoidosis (Figs. 9 and 10). Therefore, one cannot exclude the diagnosis of UIP or IPF solely on the basis of chest CT; the atypical manifestation of a common disease (UIP or IPF in interstitial lung disease) is very often as common as or sometimes more common than a less common condition. Multidisciplinary evaluation is particularly important in these cases to decide which cases can be assigned the diagnosis of IPF and which cases are more suggestive of an alternative diagnosis. For example, if the radiologic appearance is suggestive of HP, the clinician should be encouraged to aggressively seek an environmental antigen and the pathologist should be encouraged to find granulomas or other findings suggestive of HP.

It has been assumed that honeycombing on pathology and honeycombing on CT identify the same process. However, a recent study showed that there was no correlation and there was poor agreement between honeycombing on CT and pathology [42]. Although contrary to typical dogma, other facts support this finding. CT honeycombing is associated with a poor prognosis, whereas honeycombing on pathology is not [36, 44]. Also, honeycombing on pathology can be present in many different types of pulmonary fibrosis and does not carry the same high specificity in UIP diagnosis as seen in CT honeycombing. As our understanding of pulmonary fibrosis develops, the definition and significance of honeycombing on CT and pathology will undoubtedly continue to be modified.

Impact of Multidisciplinary Review on Determining Prognosis

In addition to the value of a multidisciplinary discussion in establishing the diagnosis, this approach also has prognostic ramifications. The severity of CT honeycombing, rate of worsening of honeycombing, and extent of pulmonary fibrosis are associated with poor survival in the setting of pulmonary fibrosis [15, 44–48]. Patients with a UIP diagnosis on histopathology have also been shown to have a poor prognosis relative to patients with other types of interstitial lung disease [17]. However, in other cases, the CT manifestations of disease may actually augment survival in those with a known disease; for example, patients with UIP on pathology but with an NSIP pattern on CT may have survival profiles similar to those with NSIP on pathology [17]. Among subjects with UIP on pathology, those with an indeterminate CT pattern have substantially longer median survival than those with a UIP pattern on CT [36].

The clinical findings in a patient with interstitial lung disease are also important in determining prognosis because idiopathic disease typically has a worse prognosis than secondary disease. For example, interstitial lung disease secondary to collagen vascular disease has superior survival compared with idiopathic interstitial lung disease, and this difference in survival is not simply related to differences in the underlying pathology of lung disease [49]. NSIP is common in collagen vascular disease, and NSIP has better prognosis than UIP. Park et al. [49] found that patients with collagen vascular disease and UIP on pathology had similar survival to those with NSIP (idiopathic or in the setting of collagen vascular disease) on pathology, whereas those with idiopathic UIP on pathology had significantly worse survival. Similarly, in their study of biopsy-proven UIP cases, Strand et al. [50] found that patients with collagen vascular disease had superior survival compared with those who had IPF.

Future Horizons

Recent research has shown that genetics plays an important role in the development of pulmonary fibrosis in a substantial minority of patients, which implies that it may be an important marker for diagnosis in the setting of multidisciplinary review [51–54]. Mutations in the surfactant protein A2 gene, surfactant protein C gene, and telomerase genes have been associated with pulmonary fibrosis [52–54]. The rs35705950 single-nucleotide polymorphism (SNP)—a promoter site of an airway mucin gene (*MUC5B*)—is strongly associated with IPF and familial pulmonary fibrosis [55–63]. This SNP is the dominant genetic risk factor for pulmonary fibrosis and is the sole genetic factor that has been consistently replicated in multiple studies [55–63]. Moreover, there have been no studies to date that have shown an association between this SNP and secondary causes of pulmonary fibrosis, implying that this SNP may be specific to idiopathic disease [56, 64, 65].

The rs35705950 SNP is associated with improved survival among those with IPF [57]. In a landmark study [57], the adjusted hazard ratio for minor-allele (thymine) homozygous subjects was 0.15–0.23 compared with major-allele (guanine) homozygous subjects; heterozygous subjects had an adjusted hazard ratio of 0.39–0.48 [57]. These results are interesting in that the minor allele seems to predispose people to develop IPF—which has the worst prognosis of all the types of pulmonary fibrosis [64–66]. The mechanism behind this seemingly contradic-

tory concurrence has not yet been formally studied, although early evidence suggests it may be related to enhanced innate immune host defense [67, 68]. It is likely that ongoing studies of genomics and gene expression will assist further in the diagnosis and characterization of lung fibrosis.

One practical challenge for a multidisciplinary approach to diagnosis is that the number of specialist centers with multidisciplinary review capability do not have the capacity to see all patients with fibrotic lung disease. In this context, several centers are initiating teleconferencing, with transmission of high-resolution radiologic and histologic images, to facilitate multidisciplinary review in support of community-based physicians. Further development of multidisciplinary review services may require changes in reimbursement policies by third-party payers.

Conclusion

UIP is the imaging and pathologic correlate of IPF. Multidisciplinary review is essential in establishing the diagnosis of IPF and in determining prognosis. If a confident diagnosis of UIP is made on CT, IPF is almost always the final diagnosis; lung biopsy is unnecessary in these cases. However, only about half of IPF cases can be confidently diagnosed on chest CT, and the other patients often require open

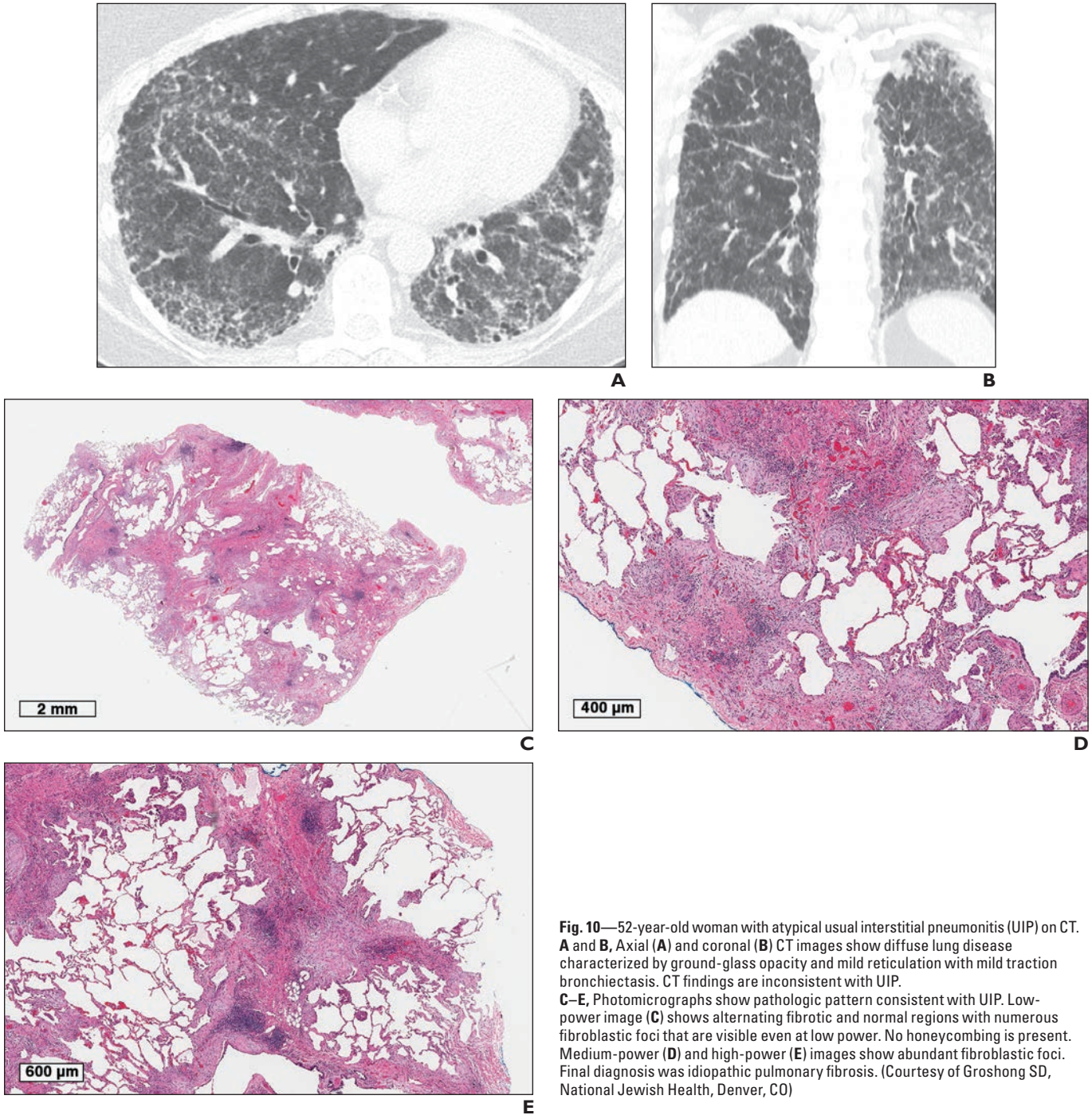

Fig. 10—52-year-old woman with atypical usual interstitial pneumonitis (UIP) on CT. **A** and **B,** Axial (**A**) and coronal (**B**) CT images show diffuse lung disease characterized by ground-glass opacity and mild reticulation with mild traction bronchiectasis. CT findings are inconsistent with UIP.
C–E, Photomicrographs show pathologic pattern consistent with UIP. Low-power image (**C**) shows alternating fibrotic and normal regions with numerous fibroblastic foci that are visible even at low power. No honeycombing is present. Medium-power (**D**) and high-power (**E**) images show abundant fibroblastic foci. Final diagnosis was idiopathic pulmonary fibrosis. (Courtesy of Groshong SD, National Jewish Health, Denver, CO)

Downloaded from www.ajronline.org by Unikilinik RWTH Aachen on 03/06/26 from IP address 134.130.15.1. Copyright ARRS. For personal use only; all rights reserved

Downloaded from www.ajronline.org by Unikilinik RWTH Aachen on 03/06/26 from IP address 134.130.15.1. Copyright ARRS. For personal use only; all rights reserved

lung biopsy for definitive diagnosis. Atypical UIP on CT—that is, a CT pattern that is inconsistent with UIP in a patient with UIP on pathology—most commonly resembles NSIP, HP, or sarcoidosis. Honeycombing on CT and honeycombing on pathology are likely dissimilar entities with different diagnostic significance and different prognostic significance. In the coming years, genetics will likely play a vital role in the multidisciplinary approach to the diagnosis of IPF and prognostication in patients with IPF.

References

1. Richeldi L, du Bois RM, Raghu G, et al. Efficacy and safety of nintedanib in idiopathic pulmonary fibrosis. *N Engl J Med* 2014; 370:2071–2082
2. King TE, Bradford WZ, Castro-Bernardini S, et al. A phase 3 trial of pirfenidone in patients with idiopathic pulmonary fibrosis. *N Engl J Med* 2014; 370:2083–2092
3. Travis WD, Costabel U, Hansell DM, et al.; ATS/ERS Committee on Idiopathic Interstitial Pneumonias. An official American Thoracic Society/European Respiratory Society statement: update of the international multidisciplinary classification of the idiopathic interstitial pneumonias. *Am J Respir Crit Care Med* 2013; 188:733–748
4. Jin GY, Lynch D, Chawla A, et al. Interstitial lung abnormalities in a CT lung cancer screening population: prevalence and progression rate. *Radiology* 2013; 268:563–571
5. Washko GR, Hunninghake GM, Fernandez IE, et al. Lung volumes and emphysema in smokers with interstitial lung abnormalities. *N Engl J Med* 2011; 364:897–906
6. Nadrous HF, Myers JL, Decker PA, Ryu JH. Idiopathic pulmonary fibrosis in patients younger than 50 years. *Mayo Clin Proc* 2005; 80:37–40
7. Raghu G, Weycker D, Edelsberg J, Bradford WZ, Oster G. Incidence and prevalence of idiopathic pulmonary fibrosis. *Am J Respir Crit Care Med* 2006; 174:810–816
8. Fell CD, Martinez FJ, Liu LX, et al. Clinical predictors of a diagnosis of idiopathic pulmonary fibrosis. *Am J Respir Crit Care Med* 2009; 181:832–837
9. Baumgartner K, Samet J, Stidley C, Colby T, Waldron J. Cigarette smoking: a risk factor for idiopathic pulmonary fibrosis. *Am J Respir Crit Care Med* 1997; 155:242–248
10. Lawson WE, Loyd JE. The genetic approach in pulmonary fibrosis: can it provide clues to this complex disease? *Proc Am Thorac Soc* 2006; 3:345–349
11. Noth I, Zangan SM, Soares RV, et al. Prevalence of hiatal hernia by blinded multidetector CT in patients with idiopathic pulmonary fibrosis. *Eur Respir J* 2011; 39:344–351
12. Lee JS, Collard HR, Anstrom KJ, et al. Anti-acid treatment and disease progression in idiopathic pulmonary fibrosis: an analysis of data from three randomised controlled trials. *Lancet Respir Med* 2014; 1:369–376
13. Hansell DM, Bankier AA, MacMahon H, McLoud TC, Müller NL, Remy J. Fleischner Society: glossary of terms for thoracic imaging. *Radiology* 2008; 246:697–722
14. Hunninghake GW, Lynch DA, Galvin JR, et al. Radiologic findings are strongly associated with a pathologic diagnosis of usual interstitial pneumonia. *Chest* 2003; 124:1215–1223
15. Lynch DA, Godwin JD, Safrin S, et al. High-resolution computed tomography in idiopathic pulmonary fibrosis: diagnosis and prognosis. *Am J Respir Crit Care Med* 2005; 172:488–493
16. Müller NL, Miller RR, Webb WR, Evans KG, Ostrow DN. Fibrosing alveolitis: CT-pathologic correlation. *Radiology* 1986; 160:585–588
17. Flaherty KR, Toews GB, Travis WD, et al. Clinical significance of histological classification of idiopathic interstitial pneumonia. *Eur Respir J* 2002; 19:275–283
18. Sumikawa H, Johkoh T, Ichikado K, et al. Usual interstitial pneumonia and chronic idiopathic interstitial pneumonia: analysis of CT appearance in 92 patients. *Radiology* 2006; 241:258–266
19. Remy-Jardin M, Giraud F, Remy J, Copin MC, Gosselin B, Duhamel A. Importance of ground-glass attenuation in chronic diffuse infiltrative lung disease: pathologic-CT correlation. *Radiology* 1993; 189:693–698
20. Nishimura K, Kitaichi M, Izumi T, Nagai S, Kanaoka M, Itoh H. Usual interstitial pneumonia: histologic correlation with high-resolution CT. *Radiology* 1992; 182:337–342
21. Leung AN, Miller RR, Müller NL. Parenchymal opacification in chronic infiltrative lung diseases: CT-pathologic correlation. *Radiology* 1993; 188:209–214
22. Ozawa Y, Suda T, Naito T, et al. Cumulative incidence of and predictive factors for lung cancer in IPF. *Respirology* 2009; 14:723–728
23. Raghu G, Collard HR, Egan JJ, et al.; ATS/ERS/JRS/ALAT Committee on Idiopathic Pulmonary Fibrosis. An official ATS/ERS/JRS/ALAT statement: idiopathic pulmonary fibrosis: evidence-based guidelines for diagnosis and management. *Am J Respir Crit Care Med* 2011 183:788–824
24. Sundaram B, Gross BH, Martinez FJ, et al. Accuracy of high-resolution CT in the diagnosis of diffuse lung disease: effect of predominance and distribution of findings. *AJR* 2008; 191:1032–1039
25. Katzenstein AL, Mukhopadhyay S, Myers JL. Diagnosis of usual interstitial pneumonia and distinction from other fibrosing interstitial lung diseases. *Hum Pathol* 2008; 39:1275–1294
26. Kuhn C 3rd, Boldt J, King TE Jr, Crouch E, Vartio T, McDonald JA. An immunohistochemical study of architectural remodeling and connective tissue synthesis in pulmonary fibrosis. *Am Rev Respir Dis* 1989; 140:1693–1703
27. King TE Jr, Schwarz MI, Brown K, et al. Idiopathic pulmonary fibrosis: relationship between histopathologic features and mortality. *Am J Respir Crit Care Med* 2001; 164:1025–1032
28. Monaghan H, Wells AU, Colby TV, du Bois RM, Hansell DM, Nicholson AG. Prognostic implications of histologic patterns in multiple surgical lung biopsies from patients with idiopathic interstitial pneumonias. *Chest* 2004; 125:522–526
29. Flaherty KR, Travis WD, Colby TV, et al. Histopathologic variability in usual and nonspecific interstitial pneumonias. *Am J Respir Crit Care Med* 2001; 164:1722–1727
30. Tokura S, Okuma T, Akira M, Arai T, Inoue Y, Kitaichi M. Utility of expiratory thin-section CT for fibrotic interstitial pneumonia. *Acta Radiol* 2014; 55:1050–1055
31. Flaherty KR, King TE Jr, Raghu G, et al. Idiopathic interstitial pneumonia: what is the effect of a multidisciplinary approach to diagnosis? *Am J Respir Crit Care Med* 2004; 170:904–910
32. Flaherty KR, Andrei AC, King TE Jr, et al. Idiopathic interstitial pneumonia: do community and academic physicians agree on diagnosis? *Am J Respir Crit Care Med* 2007; 175:1054–1060
33. Nicholson AG, Addis BJ, Bharucha H, et al. Inter-observer variation between pathologists in diffuse parenchymal lung disease. *Thorax* 2004; 59:500–505
34. Lynch DA. Lung disease related to collagen vascular disease. *J Thorac Imaging* 2009; 24:299–309
35. Fischer A, Antoniou KM, Brown KK, et al.; ERS/ATS Task Force on Undifferentiated Forms of CTD-ILD. An official European Respiratory Society/American Thoracic Society research statement: interstitial pneumonia with autoimmune features. *Eur Respir J* 2015; 46:976–987
36. Flaherty KR, Thwaite EL, Kazerooni EA, et al. Radiological versus histological diagnosis in UIP and NSIP: survival implications. *Thorax* 2003; 58:143–148
37. Tsubamoto M, Müller NL, Johkoh T, et al. Pathologic subgroups of nonspecific interstitial pneumonia: differential diagnosis from other idiopathic interstitial pneumonias on high-resolution computed tomography. *J Comput Assist Tomogr* 2005; 29:793–800
38. Johkoh T, Müller NL, Cartier Y, et al. Idiopathic interstitial pneumonias: diagnostic accuracy of thin-section CT in 129 patients. *Radiology* 1999; 211:555–560
39. Silva CI, Müller NL, Lynch DA, et al. Chronic hypersensitivity pneumonitis: differentiation from idiopathic pulmonary fibrosis and nonspecific in-

Downloaded from www.ajronline.org by Unikilinik RWTH Aachen on 03/06/26 from IP address 134.130.15.1. Copyright ARRS. For personal use only; all rights reserved

terstitial pneumonia by using thin-section CT. *Radiology* 2008; 246:288–297

40. Hunninghake GW, Zimmerman MB, Schwartz DA, et al. Utility of a lung biopsy for the diagnosis of idiopathic pulmonary fibrosis. *Am J Respir Crit Care Med* 2001; 164:193–196
41. Swensen SJ, Aughenbaugh GL, Myers JL. Diffuse lung disease: diagnostic accuracy of CT in patients undergoing surgical biopsy of the lung. *Radiology* 1997; 205:229–234
42. Chung JH, Chawla A, Peljto AL, et al. CT scan findings of probable usual interstitial pneumonitis have a high predictive value for histologic usual interstitial pneumonitis. *Chest* 2015; 147:450–459
43. Sverzellati N, Wells AU, Tomassetti S, et al. Biopsy-proved idiopathic pulmonary fibrosis: spectrum of nondiagnostic thin-section CT diagnoses. *Radiology* 2010; 254:957–964
44. Gay S, Kazerooni E, Toews G, et al. Idiopathic pulmonary fibrosis: predicting response to therapy and survival. *Am J Respir Crit Care Med* 1998; 157:1063–1072
45. Nagao T, Nagai S, Hiramoto Y, et al. Serial evaluation of high-resolution computed tomography findings in patients with idiopathic pulmonary fibrosis in usual interstitial pneumonia. *Respiration* 2002; 69:413–419
46. Sumikawa H, Johkoh T, Colby TV, et al. Computed tomography findings in pathological usual interstitial pneumonia: relationship to survival. *Am J Respir Crit Care Med* 2008; 177:433–439
47. Shin KM, Lee KS, Chung MP, et al. Prognostic determinants among clinical, thin-section CT, and histopathologic findings for fibrotic idiopathic interstitial pneumonias: tertiary hospital study. *Radiology* 2008; 249:328–337
48. Hwang JH, Misumi S, Curran-Everett D, Brown KK, Sahin H, Lynch DA. Longitudinal follow-up of fibrosing interstitial pneumonia: relationship between physiologic testing, computed tomography changes, and survival rate. *J Thorac Imaging* 2011; 26:209–217
49. Park JH, Kim DS, Park IN, et al. Prognosis of fibrotic interstitial pneumonia: idiopathic versus collagen vascular disease–related subtypes. *Am J Respir Crit Care Med* 2007; 175:705–711
50. Strand MJ, Sprunger D, Cosgrove GP, et al. Pulmonary function and survival in idiopathic vs secondary usual interstitial pneumonia. *Chest* 2014; 146:775–785
51. Steele MP, Speer MC, Loyd JE, et al. Clinical and pathologic features of familial interstitial pneumonia. *Am J Respir Crit Care Med* 2005; 172:1146–1152
52. Nogee LM, Dunbar AE 3rd, Wert SE, Askin F, Hamvas A, Whitsett JA. A mutation in the surfactant protein C gene associated with familial interstitial lung disease. *N Engl J Med* 2001; 344:573–579
53. Wang Y, Kuan PJ, Xing C, et al. Genetic defects in surfactant protein A2 are associated with pulmonary fibrosis and lung cancer. *Am J Hum Genet* 2009; 84:52–59
54. Armanios MY, Chen JJ, Cogan JD, et al. Telomerase mutations in families with idiopathic pulmonary fibrosis. *N Engl J Med* 2007; 356:1317–1326
55. Seibold MA, Wise AL, Speer MC, et al. A common MUC5B promoter polymorphism and pulmonary fibrosis. *N Engl J Med* 2011; 364:1503–1512
56. Borie R, Crestani B, Dieude P, et al. The MUC5B variant is associated with idiopathic pulmonary fibrosis but not with systemic sclerosis interstitial lung disease in the European Caucasian population. *PLoS One* 2013; 8:e70621
57. Peljto AL, Zhang Y, Fingerlin TE, et al. Association between the MUC5B promoter polymorphism and survival in patients with idiopathic pulmonary fibrosis. *JAMA* 2013; 309:2232–2239
58. Stock CJ, Sato H, Fonseca C, et al. Mucin 5B promoter polymorphism is associated with idiopathic pulmonary fibrosis but not with development of lung fibrosis in systemic sclerosis or sarcoidosis. *Thorax* 2013; 68:436–441
59. Fingerlin TE, Murphy E, Zhang W, et al. Genome-wide association study identifies multiple susceptibility loci for pulmonary fibrosis. *Nat Genet* 2013; 45:613–620
60. Zhang Y, Noth I, Garcia JG, Kaminski N. A variant in the promoter of MUC5B and idiopathic pulmonary fibrosis. *N Engl J Med* 2011; 364: 1576–1577
61. Horimasu Y, Ohshimo S, Bonella F, et al. MUC5B promoter polymorphism in Japanese patients with idiopathic pulmonary fibrosis. *Respirology* 2015; 20:439–444
62. Noth I, Zhang Y, Ma SF, et al. Genetic variants associated with idiopathic pulmonary fibrosis susceptibility and mortality: a genome-wide association study. *Lancet Respir Med* 2013; 1:309–317
63. Wei R, Li C, Zhang M, et al. Association between MUC5B and TERT polymorphisms and different interstitial lung disease phenotypes. *Transl Res* 2014; 163:494–502
64. Peljto AL, Steele MP, Fingerlin TE, et al. The pulmonary fibrosis-associated MUC5B promoter polymorphism does not influence the development of interstitial pneumonia in systemic sclerosis. *Chest* 2012; 142:1584–1588
65. Stock CJ, Sato H, Fonseca C, et al. Mucin 5B promoter polymorphism is associated with idiopathic pulmonary fibrosis but not with development of lung fibrosis in systemic sclerosis or sarcoidosis. *Thorax* 2013; 68:438–441
66. Hunninghake GM, Hatabu H, Okajima Y, et al. MUC5B promoter polymorphism and interstitial lung abnormalities. *N Engl J Med* 2013; 368:2192–2200
67. Molyneaux PL, Cox MJ, Willis-Owen SA, et al. The role of bacteria in the pathogenesis and progression of idiopathic pulmonary fibrosis. *Am J Respir Crit Care Med* 2014; 190:906–913
68. Roy MG, Livraghi-Butrico A, Fletcher AA, et al. Muc5b is required for airway defence. *Nature* 2014; 505:412–416

FOR YOUR INFORMATION

This article is available for CME and Self-Assessment (SA-CME) credit that satisfies Part II requirements for maintenance of certification (MOC). To access the examination for this article, follow the prompts associated with the online version of the article.